

Supporting Information

Multimodal *In Vivo* Imaging Exposes the Voyage of Nanoparticles in Tumor Microcirculation

Randall Toy^{1,2,3}, Elliott Hayden^{1,3}, Andrew Camann^{1,3}, Zachary Berman^{2,3}, Peter Vicente^{1,3}, Emily Tran^{1,3}, Joseph Meyers^{1,3}, Jenna Pansky^{1,3}, Pubudu M. Peiris^{1,3}, Hanping Wu^{2,3}, Agata Exner^{1,2,3,4}, David Wilson^{1,2,3,4}, Ketan B. Ghaghada^{5,6}, and Efstathios Karathanasis^{1,2,3,4,*}

¹Department of Biomedical Engineering, Case Western Reserve University, Cleveland, Ohio

²Department of Radiology, Case Western Reserve University, Cleveland, Ohio

³Case Center for Imaging Research, Case Western Reserve University, Cleveland, Ohio

⁴Case Comprehensive Cancer Center, Case Western Reserve University, Cleveland, Ohio

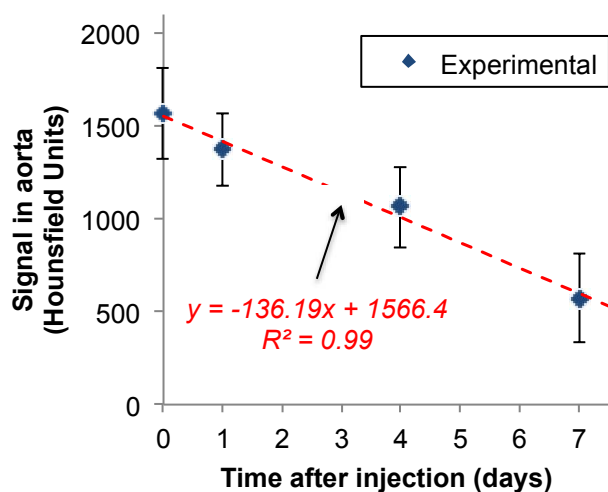
⁵Edward B. Singleton Department of Pediatric Radiology, Texas Children's Hospital, Houston, Texas

⁶Department of Radiology, Baylor College of Medicine, Houston, Texas

* Author to whom correspondence should be addressed: Efstathios Karathanasis

email: stathis@case.edu

Supporting Figures



Supporting Figure S1. Blood clearance of the 100-nm liposomal contrast agent in rats with orthotopic 13762 MAT B III tumors. The time–attenuation curve in the aorta was measured at multiple time points using a micro-CT system after systemic administration of the liposomal contrast agent encapsulating 110 mg/mL iodine (dose: 2.25 g/kg iodine; n=3 animals). Signal is shown in Hounsfield Units (HU). The pre-injection attenuation in the aorta (t<0) was ~150 HU. Imaging was performed immediately after post-injection (t=0) and 1, 4 and 7 days post-injection.