

Supplementary Figure S1

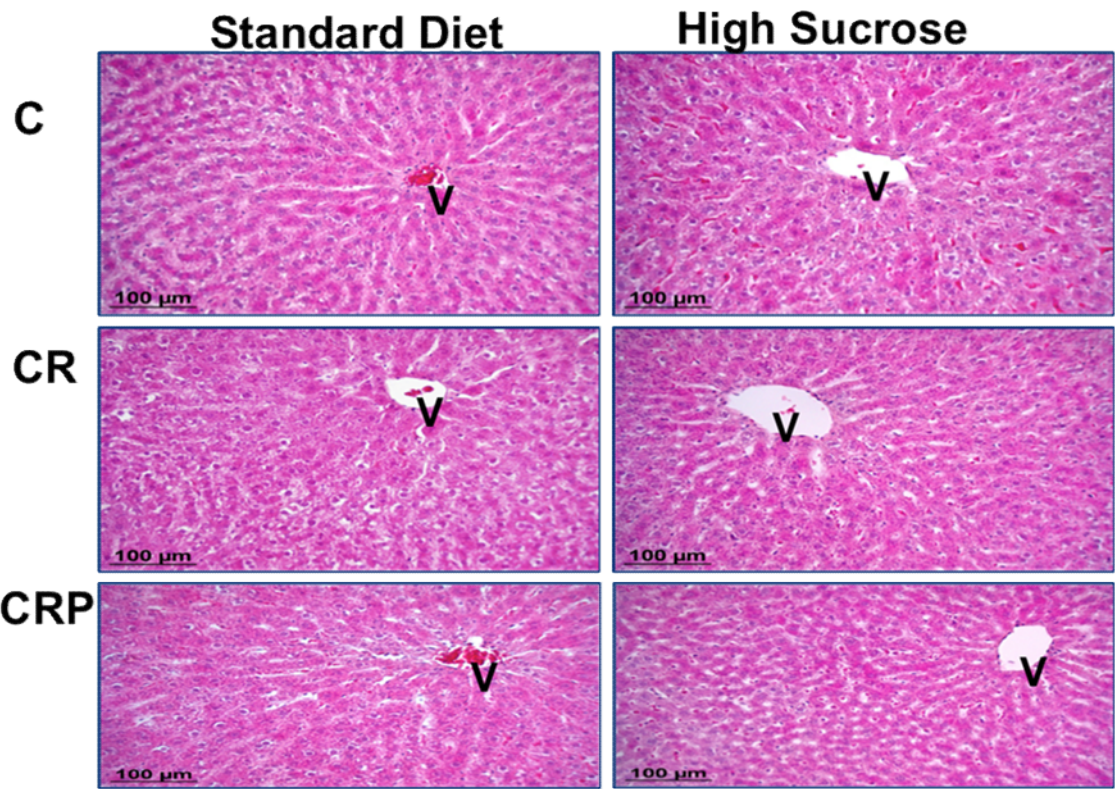


Figure S1: Representative liver slides stained with hematoxylin/eosin (x20) of C, CR and CRP groups under SD or HS diet at 6 months of age. V, indicates central vein.